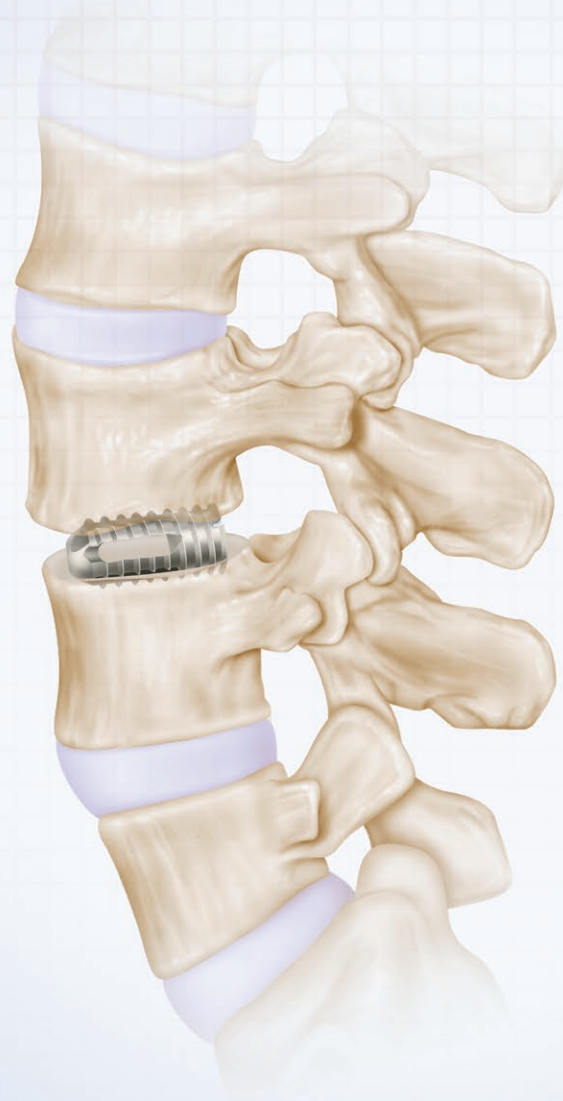


# ASFORA BULLET CAGE<sup>®</sup> SYSTEM

## SURGICAL PROCEDURE MANUAL



**MEDICAL  
DESIGNS** L.L.C.

*Surgical Instruments Designed by Medical Professionals*

# Surgical Procedure Manual

Posterior Lumbar Interbody Fusion (PLIF) with the Asfora Bullet Cage®  
Transforaminal Lumbar Interbody Fusion (TLIF) with the Asfora Bullet Cage®  
Anterior Lumbar Interbody Fusion (ALIF) with the Asfora Bullet Cage®

## Introduction

### Section I:

#### **Posterior Lumbar Interbody Fusion (PLIF) with the Asfora Bullet Cage®**

Step One: Magnetic Resonance Imaging Analysis  
Step Two: Patient Positioning and Skin Marking  
Step Three: Exposure of the Spine  
Step Four: Decompression and Approach  
Step Five: Preparation of the Disc Space and Cage Insertion  
Step Six: Wound Closure  
Postoperative Care  
Revision, Removal or Replacement

### Section II:

#### **Transforaminal Lumbar Interbody Fusion (TLIF) with the Asfora Bullet Cage®**

Step One: Magnetic Resonance Imaging Analysis  
Step Two: Patient Positioning and Skin Marking  
Step Three: Exposure of the Spine  
Step Four: Decompression and Approach  
Step Five: Preparation of the Disc Space and Cage Insertion  
Step Six: Wound Closure  
Postoperative Care  
Revision, Removal or Replacement

### Section III:

#### **Anterior Lumbar Interbody Fusion (ALIF) with the Asfora Bullet Cage®**

Step One: Magnetic Resonance Imaging Analysis  
Step Two: Patient Positioning and Skin Marking  
Step Three: Exposure of the Spine  
Step Four: Decompression and Approach  
Step Five: Preparation of the Disc Space and Cage Insertion  
Step Six: Wound Closure  
Postoperative Care  
Revision, Removal or Replacement

## Introduction

Interbody fusion has been applied to the cervical, thoracic and lumbar spinal segments using a variety of techniques. In the 1950's, neurosurgical pioneer Dr. R. Cloward, MD, developed the original methodology for posterior lumbar interbody fusion (PLIF) across an intervertebral disc space and had excellent clinical outcomes. Biomechanically, PLIF is an ideal fusion, as it restores weight bearing to the anterior structures of the spine. The PLIF procedure restores the disc height, enlarges the neural foramen, decompresses the nerve roots, restores the annulus to adequate tension and immobilizes the unstable, degenerated intervertebral disc area.

The lumbar disc space was originally approached by Dr. Cloward posteriorly; however, more recently, others have described alternative routes such as the posterolateral approach which has been denominated transforaminal lumbar interbody fusion (TLIF) and the anterior lumbar approach (ALIF). The advantage claimed for the ALIF and TLIF is that the risk of dural sac or nerve root damage is decreased. In all approaches, bone or interbody devices known as "cages" filled with bone are placed in the disc space and the end result is essentially the same.

### Asfora Bullet Cage®

The Asfora Bullet Cage® (ABC) is comprised of a threaded titanium alloy interbody fusion device (cage) and threaded cap. The ABC is a threaded, self-tapping, bullet-shaped, hollow-body device designed to immobilize adjacent vertebrae and promote arthrodesis (fusion) across the disc space. The ABC is available in ten sizes; five diameters (10 mm, 12 mm, 14 mm, 16 mm, 18 mm) and two lengths (21 mm or 25 mm). These sizes are suitable for interbody fusions done through the posterior (PLIF), posterolateral/transforaminal (TLIF) and anterior (ALIF) approaches.

### Indications

The Asfora Bullet Cage® (ABC) is indicated for spinal fusion procedures in skeletally mature patients with degenerative disc disease (DDD) and instability in the lumbar spine at one or two contiguous levels from L2 to S1. DDD for lumbar systems is defined as back pain of discogenic origin with degeneration of the disc confirmed by history and radiographic studies. The DDD patients may also have up to Grade I spondylolisthesis at the involved level(s). The ABC cage devices are used with autogenous bone graft. Patients should be skeletally mature and have had at least six (6) months of non-operative treatment prior to implant. When implanted via a posterior (PLIF, TLIF) approach, this device should be used with supplemental fixation.

### Contraindications

The Asfora Bullet Cage® is not indicated for use in patients with Grade II and above spondylolisthesis. The ABC should not be implanted in patients with an active infection at the operative site or with an allergy to titanium or titanium alloy.

Asfora Bullet Cage®



## Section I

### Posterior Lumbar Interbody Fusion (PLIF) with the Asfora Bullet Cage®

The information presented in this brochure simply represents a further refinement of the techniques previously described in the literature. Revision and removal procedures are also discussed in this brochure.

#### Step One: Magnetic Resonance Imaging Analysis

- Before scrubbing, the surgeon should check the patient's MRI films. Axial cuts should be measured for anterior-posterior diameter of the vertebrae to be fused (Fig. I-1A).
- If the diameter is greater than 35 mm, a 25 mm length cage should be used. If the diameter is smaller than 35 mm, a 21 mm cage is preferred.
- On the sagittal views, the disc space height is also measured; however, the final decision regarding diameter of the cage is made intraoperatively (Fig. I-1B).

#### Step Two: Patient Positioning and Skin Marking

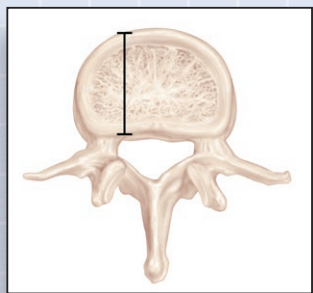
- The patient should be positioned prone on the operative table. Care should be taken to avoid any pressure over the abdomen in order to decrease intraoperative epidural bleeding.
- The patient should now be prepped and draped per standard protocol.
- Intraoperative fluoroscopy in the lateral plane is used to localize and verify the correct level(s) and guide the location of the skin incision (Fig. I-2).

#### Step Three: Exposure of the Spine

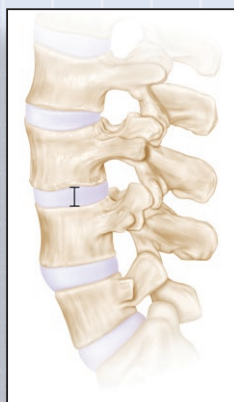
- For a single level fusion, an approximate 5 cm in length, vertical incision is made across the skin mark. The incision should be taken through the skin, the subcutaneous tissue and the muscle fascia.
- Separate the paraspinal muscles from the spinous process and lamina of the two vertebrae to be fused, and then apply a retractor of choice, such as a McCullough (or similar) retractor (Fig. I-3).
- The microscope is then brought into the operative field (unless the surgeon has chosen to use surgical loops).

#### Step Four: Decompression and Approach

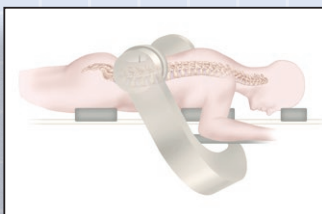- Use a high speed drill and Kerrison rongeurs to remove part of the lamina and medial half of the facet joint initially on the right side. Preserve all bone material, including bone dust, to later fill the cages or perform a posterolateral fusion (Fig. I-4A).
- Incise the ligamentum flavum as laterally as possible to minimize exposure of the dura. By preserving most of the ligamentum flavum, not only is the dural sac protected, but it may also decrease postoperative epidural fibrosis. Foraminotomy is then carried out in the standard fashion. The amount of the facet joint removed will depend on the exposure needed to minimize dural retraction.



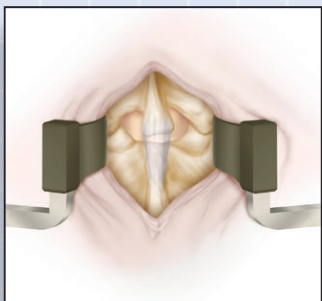
(Fig. I-1A)



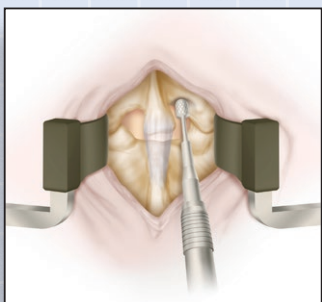
(Fig. I-1B)



(Fig. I-2)



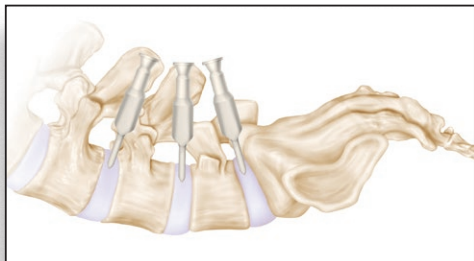
(Fig. I-3)



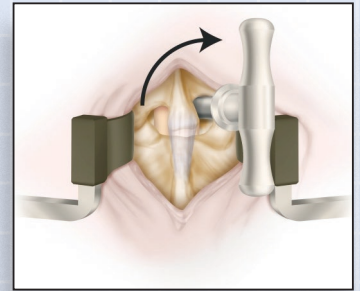
(Fig. I-4A)

## Posterior Lumbar Interbody Fusion (PLIF) with the Asfora Bullet Cage<sup>®</sup>

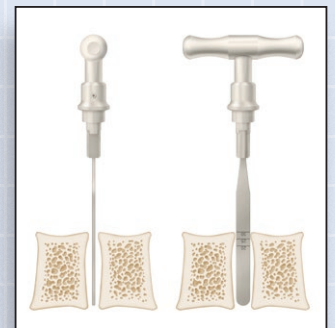- During exposure of the annulus fibrosus, care should be taken to preserve all epidural vessels by means of meticulous dissection and mobilization of these fragile veins. Retract the traversing nerve root and dural sac medially with nerve root retractors.
- Enter the disc space on the right side. Remove some disc space material to accommodate the disc space distractor. Initially, try a 6 mm disc space distractor. If loose, the 8 mm distractor should be tried (Fig. I-4B & I-4C).
- Insert the disc space distractor in a position parallel to the disc space to approximately 25-30 mm deep. Rotate the distractor 90 degrees and remove the handle. The distractor must be held firmly between the two vertebrae. Select the appropriate size cages. The diameter of the cage should be approximately 6 mm larger than the size of the distractor. For example, if the distractor is 6 mm, a 12 mm diameter cage should be used.
- Attention is now focused on the left side. As on the right, remove some of the lamina, facet joint, and ligamentum flavum. Avoid exposing the dura by preserving most of the ligamentum flavum. The disc space distractor on the right side indicates the location and orientation of the disc space on the left. The amount of lamina and facet joint removed should be the minimal amount, sufficient to accommodate the appropriate drill guide (Fig. I-4D).
- The dural sac, traversing nerve root, exiting nerve root, and epidural vessels should be retracted with nerve root retractors (usually 3 retractors are used) to expose the disc space. Having well protected the neural and vascular elements, insert the appropriate drill guide. The drill guide should be advanced all the way to the annulus. The inner diameter of the drill guide selected should be equal to the diameter of the cage to be implanted and they are labeled accordingly (Fig. I-4E).
- The drill guide should be angled five (5) degrees medially and should have similar direction in the vertical plane as the disc space distractor (Fig. I-4F).
  - at L5-S1, the angle is usually directed caudally
  - at L4-5, the angle is usually straight down
  - at L3-4, the angle is usually directed cephalad
- Incise the annulus with a number 11 scalpel. Use a centering punch to verify the position of the drill guide. The drill guide should be perfectly centered around the centering punch when the centering punch is placed into the disc space.



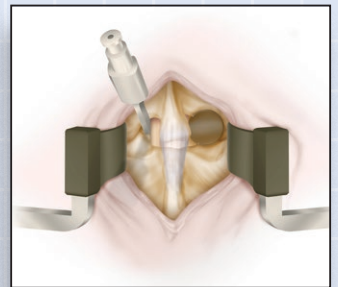
(Fig. I-4F)



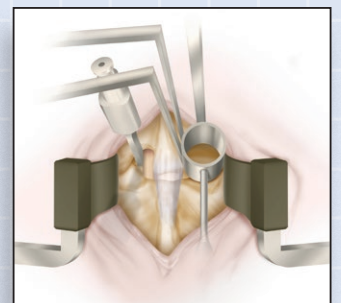
(Fig. I-4B)



(Fig. I-4C)



(Fig. I-4D)

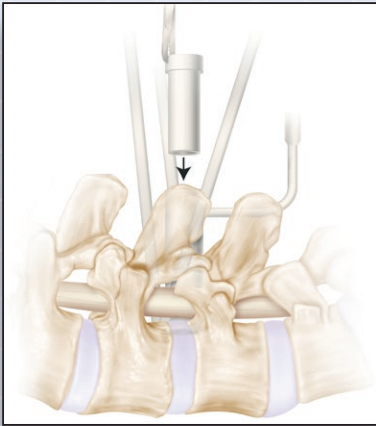


(Fig. I-4E)

## Section I

### Posterior Lumbar Interbody Fusion (PLIF) with the Asfora Bullet Cage®

#### Step Five: Preparation of the Disc Space and Cage Insertion



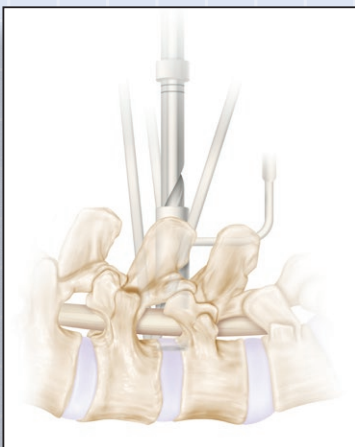
(Fig. I-5A)



(Fig. I-5B)



(Fig. I-5C)



(Fig. I-5D)

- Insert an inner cannula into the drill guide. The inner cannula should be 2 mm smaller in diameter than the diameter of the cage to be implanted. For example, if the cage to be implanted is 12 mm in diameter, insert the 10 mm inner cannula (Fig. I-5A).
- While drilling, the nerve root retractors should be left in place along with the drill guide to further provide protection of the neural and vascular structures. Once the disc space is entered, an aggressive discectomy is not required as the drill will remove most of the disc material.
- Adjust the drill stopper with the set-screw so the drill advances approximately 4 mm beyond the length of the selected cage (Fig. I-5B & I-5C). Begin by drilling the disc space with the 6 mm drill (Fig. I-5D). Advance stepwise to the largest size drill that fits the inner cannula. For example, if the inner cannula is 10 mm in diameter, the disc space is drilled starting with a 6 mm drill, then 8 mm and then 10 mm. Rotate the drill in a clockwise fashion. Continue this rotation during withdrawal of the drill so that all disc material and bone are removed.
- Once drilling is complete, remove the inner cannula. With microscope or loop guidance, inspect the disc space and remove all residual disc material. If necessary, the disc space surface may also be curetted.
- Having cleaned up the disc space, now insert the selected cage that has been previously filled with autogenous bone preserved from the lamina and facet joints from Step Four, use the cage inserter to advance the cage until the distal marking on the shaft is flush with the top surface of the drill guide (Fig. I-5E). This will countersink the cage by 4-5 mm. Note that the cage has six equidistant slots around its circumference and therefore may be placed in any position.
- Close the cage by inserting the threaded end-cap, using the end-cap screwdriver (Fig. I-5F). Remove the drill guide followed by the nerve root retractors and the disc space distractor.
- Take an x-ray (or fluoroscopy) to check the position of the cage. If necessary, minor adjustments may be made using the end-cap screwdriver to advance the cage.
- Attention is now focused on the right side. Follow the procedure outlined above to implant the second cage of equal dimensions into the disc space on the right. Once the second cage is implanted another x-ray (or fluoroscopy) should be taken to verify cage positioning.

## Section I

### Posterior Lumbar Interbody Fusion (PLIF) with the Asfora Bullet Cage®

#### Step Six: Wound Closure

Standard closure is undertaken. Re-approximate the muscle fascia with 0-PDS, the subcutaneous tissue with 3-0 PDS and the skin with a 4-0 Vicryl. A lumbar drain is not routinely required.

#### Postoperative Care

On the day following surgery, ambulate the patient with a Warm'N'Form lumbar brace. The brace should be worn for a minimum of six weeks. The patient may be ready for discharge one to two days following surgery. Schedule follow-up visits as per standard Follow-up protocol.

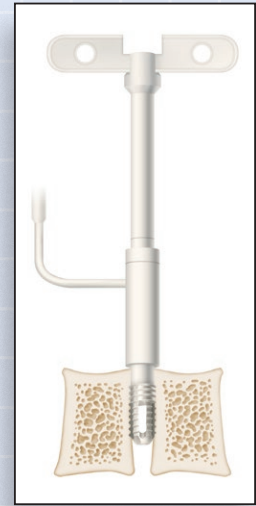
#### Revision, Removal or Replacement

Circumstances can develop post-implant that may require revision of the implant site or surrounding area, removal or replacement of the implanted device. The most frequent reason(s) for further surgery post-implant are discussed below.

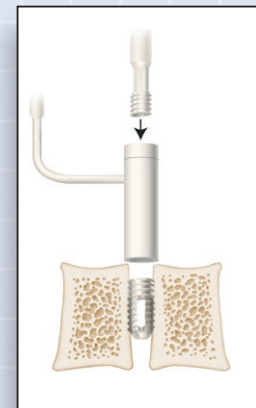
#### Failure of Fusion (non-union)

The diagnosis of non-union should only be entertained two years following implant of the ABC. Symptomatic patients should undergo x-rays in flexion and extension, and a CT scan of the LS spine. The diagnosis of pseudoarthrosis is confirmed if motion is present at the implanted level, usually accompanied by radiolucent shades around the cage and failure of new bone formation. Further surgical intervention in these cases is usually indicated. Surgical options include the use of supplemental fixation such as the use of pedicle screws and posterior lateral fusion or re-do of the PLIF.

To revise the PLIF, the wound is opened in the usual fashion utilizing magnification (either microscope or loops). The neural elements are protected with the root retractors. The end-cap of the cage is removed with the appropriate tool and the cage applier that was used for insertion is connected to the cage and rotated counter clockwise. Once the cage is removed, the vertebral end plates are inspected and bone/debris removed with a curette as needed. The endplates should be clear of cartilage and disc material as well. A new cage filled with autogenous bone or bone substitute is inserted. For better purchase strength, the new cage should be a size larger than the removed cage. The procedure should be repeated on the contralateral side.



(Fig. I-5E)



(Fig. I-5F)

## Section I

### Posterior Lumbar Interbody Fusion (PLIF) with the Asfora Bullet Cage®

#### Implant Migration or Misplacement

In this instance, no action is needed unless the cage compresses neural or vascular elements or is significantly (>25%) out of the disc space. If the cage protrudes beyond 25%, the technique for cage removal and replacement (see Fusion Failure described above), is employed. Note that there may be times when it may be more prudent to simply advance the cage forward or backward depending on its position in relation to the disc space.

If cage migration or misplacement is associated with intra-abdominal vascular injury with acute loss of blood, an emergent laparotomy by a vascular surgeon is indicated. If injury to other structures such as bowel or ureter is suspected, a general surgeon or urologist should be consulted and laparotomy may be indicated.

#### Infection

If there is clinical and radiological evidence of disc space infection, the cage should be removed and not replaced (see Fusion Failure above). Natural fusion may occur over time without any instrumentation. Re-fusion of the involved vertebral level may be indicated if unstable, once there is no evidence of ongoing infection.

#### Implant Breakage

Breakage will necessitate removal and replacement if associated with failure of fusion or implant migration.

Other conditions that may lead to further surgery, but not necessarily explantation of the cage include:

- residual disc or recurrent herniation associated with pain
- spontaneous or traumatic bone fractures
- marked subsidence of cage



## Section II

### Transformational Lumbar Interbody Fusion (TLIF) with the Asfora Bullet Cage®

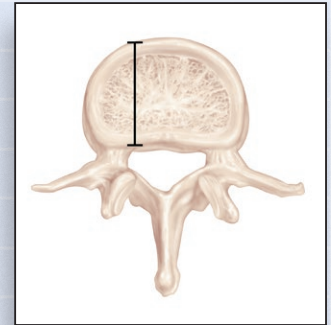
The procedure previously described for PLIF may be considered by some as bilateral TLIF in view of the fact that the spinous process is not removed and the drill guide is placed laterally following facetectomy and directed medially. In this section, a minimally invasive, unilateral, micro-TLIF is described which is performed through a paramedian incision utilizing a tube system, such as the METRx™ system from Medtronic-Sofamor Danek or Aperture™ system from DePuy/AcroMed. When the TLIF is unilateral, supplemental instrumentation, such as percutaneous pedicle screws, should be utilized.

#### Step One: Magnetic Resonance Imaging Analysis

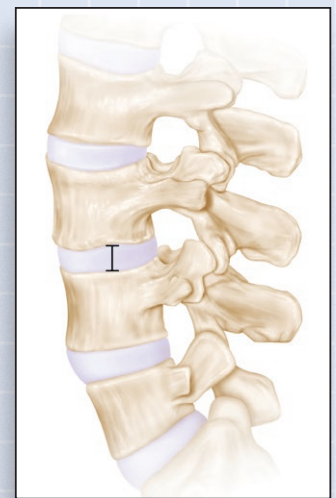
- Before scrubbing, the surgeon should check the patient's MRI films. Axial cuts should be measured for anterior-posterior diameter of the vertebrae to be fused (Fig. II-1A).
- If the diameter is greater than 35 mm, a 25 mm length cage should be used. If the diameter is smaller than 35 mm, a 21 mm cage is preferred.
- On the sagittal views, the disc space height is also measured; however, the final decision regarding diameter of the cage is made intraoperatively (Fig. II-1B).

#### Step Two: Patient Positioning and Skin Marking

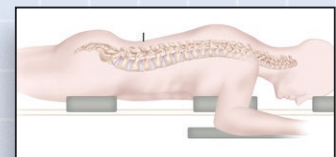
- The patient should be positioned prone on a radiolucent type of operative table. Care should be taken to avoid any pressure over the abdomen in order to decrease intraoperative epidural bleeding (Fig. II-2A).
- The patient should now be prepped and draped per standard protocol.
- Two intraoperative C-arm fluoroscopes are positioned for lateral and antero-posterior views of the spine and used to localize and verify the correct disc level(s) and pedicle location. (Fig. II-2B)



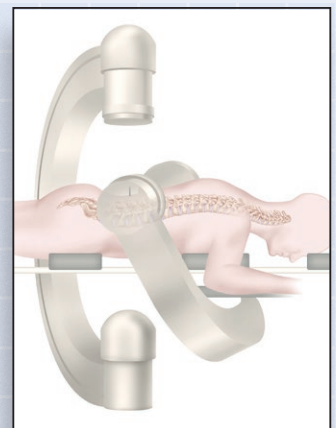
(Fig. II-1A)



(Fig. II-1B)



(Fig. II-2A)

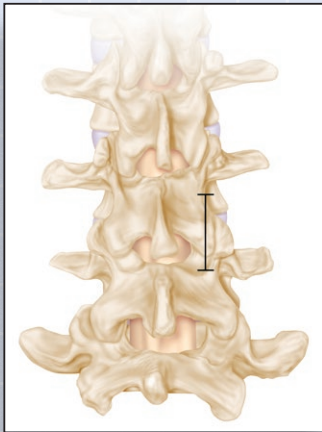


(Fig. II-2B)

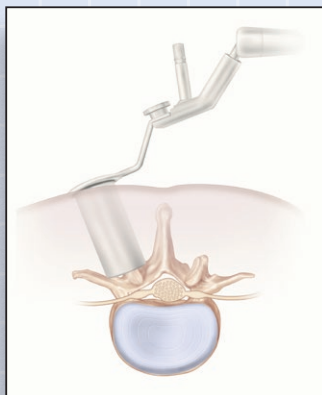
## Section II

### Transformational Lumbar Interbody Fusion (TLIF) with the Asfora Bullet Cage®

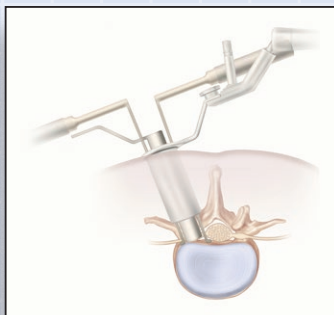
#### Step Three: Exposure of the Spine



(Fig. II-3A)



(Fig. II-3B)



(Fig. II-4)

- At the level of the proposed fusion, an incision approximately 2.5 cm in length is made across the level of the disc space, in a paramedian position in line with the pedicles. The incision should be taken through the skin, the subcutaneous tissue and the muscle fascia (Fig. II-3A).
- The METRx™ instruments (Medtronic-SofamorDanek) or similar tube system, are now used to approach and visualize the spine as described below.
- A guide wire is inserted through the small incision towards the lamina and a cannulated soft tissue dilator is passed over the guide wire, directed towards the inferior aspect of the superior lamina, which should be at the level of the intended disc space. The guide wire is then removed.
- Sequentially larger dilators are passed over the first dilator. Markings on the side of the dilators indicate the depth from the skin surface. A 22 mm tubular retractor of appropriate length is chosen and advanced over the final dilator. After it has been locked into position with the articulated, table mounted retractor arm, the dilators are removed (Fig. II-3B). The microscope is brought into the operative field. Residual soft tissue is cleared from the laminal surface exposing the lamina and ligamentum flavum.

#### Step Four: Decompression and Approach

- Utilizing high speed drills and Kerrison rongeurs, partial laminectomy and facetectomy are performed. All bone removed is preserved. The ligamentum flavum is incised lateral to the dural sac and the annulus is exposed. Care is taken not to expose dura by preserving the ligamentum flavum and not sacrifice epidural vessels as described in the PLIF technique in Section I.
- Adequate decompression of the dural sac and exiting nerve root is then performed as needed.
- Nerve root retractors are used to protect the dural sac, the traversing and exiting nerve roots as described in Section I, PLIF procedure. Usually three retractors are used.
- A drill guide of appropriate size, created to fit the tube system, is advanced all the way to the annulus (Fig. II-4).

## Section II

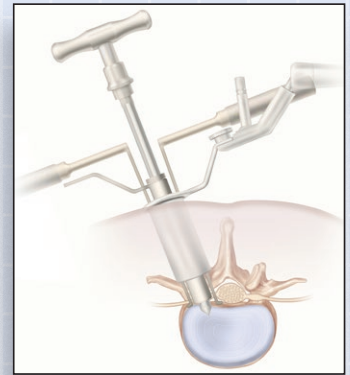### Transformational Lumbar Interbody Fusion (TLIF) with the Asfora Bullet Cage®

#### Step Five: Preparation of the Disc Space and Cage Insertion

- Using a No.11 blade the annulus is incised and discectomy carried out.
- An inner cannula is placed into the drill guide and the disc space is drilled (Fig. II-5A). This inner cannula decreases the inner diameter of the drill guide by 2mm. For example, if the intended cage is 12 mm in diameter, start with a 6 mm drill and then follow by the 8 mm and 10 mm drills. If a 14 mm cage is selected, an 8 mm, then 10 mm and then 12 mm drill sequence is used.
- Care should be taken to put a stopper on the drill bits at the desired depth level as indicated by the measured markings on the shaft of the drill and in addition, confirm depth level with fluoroscopy (Fig. II-5B).
- Remove the inner cannula and with the microscope visualize the disc space and remove all debris and residual disc. Pack the disc space with the preserved bone from the lamina and facet joint.
- The desired cage is filled with the same preserved bone and then threaded into the disc space under direct vision with microscope guidance. There are also markings on the shaft of the inserter which guide the depth of the cage. However, C-arm fluoroscopy should always be used to confirm position. Apply the closing cap to the cage.
- With the cage in place, the drill guide and retractors are now removed and percutaneous pedicle screws may be inserted through the same incision (Fig. II-5C).
- If a second cage is desired, a contralateral incision should be made and the technique repeated. A variation of this procedure would be through a midline incision for bilateral approach (Fig. II-5D).

#### Step Six: Wound Closure

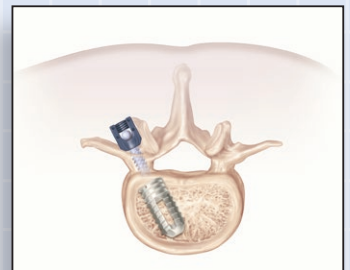- Standard closure is carried out. Re-approximate the muscle fascia with 0-PDS, the subcutaneous tissue with 3-0 PDS and the skin with a 4-0 Vicryl. Routinely, a lumbar drain is not required.



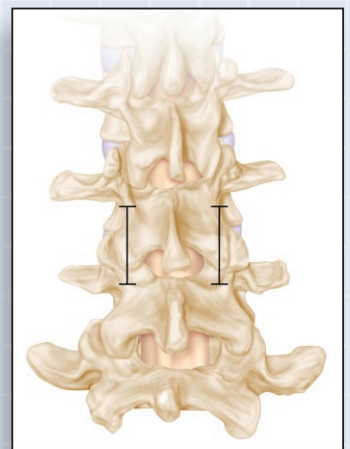
(Fig. II-5A)



(Fig. II-5B)



(Fig. II-5C)



(Fig. II-5D)

## Section II

### Transformational Lumbar Interbody Fusion (TLIF) with the Asfora Bullet Cage®

#### Postoperative Care

On the day following surgery, ambulate the patient with a Warm'N'Form lumbar brace. The brace should be worn for a minimum of six weeks. The patient may be ready for discharge one to two days following surgery. Schedule follow-up visits as per standard Follow-up protocol.

#### Revision, Removal or Replacement

Circumstances can develop post-implant that may require revision of the implant site or surrounding area, removal or replacement of the implanted device. The most frequent reason(s) for further surgery post-implant are discussed below.

#### Failure of Fusion (non-union)

The diagnosis of non-union should only be entertained two years following implant of the ABC. Symptomatic patients should undergo x-rays in flexion and extension, and a CT scan of the LS spine. The diagnosis of pseudoarthrosis is confirmed if motion is present at the implanted level, usually accompanied by radiolucent shades around the cage and screws and failure of new bone formation. Further surgical intervention in these cases is usually indicated. Surgical options include the use of supplemental fixation such as the use of contralateral pedicle screws and posterior lateral fusion or contralateral TLIF.

#### Implant Migration or Misplacement

In this instance, no action is needed unless the cage compresses neural or vascular elements or is significantly (>25%) out of the disc space. If the cage protrudes beyond 25%, the technique for cage removal and replacement (see Fusion Failure described above), is employed. Note that there may be times when it may be more prudent to simply advance the cage forward or backward depending on its position in relation to the disc space.

If cage migration or misplacement is associated with intra-abdominal vascular injury with acute loss of blood, an emergent laparotomy by a vascular surgeon is indicated. If injury to other structures such as bowel or ureter is suspected, a general surgeon or urologist should be consulted and laparotomy may be indicated.

#### Infection

If there is clinical and radiological evidence of disc space infection, the cage should be removed and not replaced (see Fusion Failure above). Natural fusion may occur over time without any instrumentation. Re-fusion of the involved vertebral level may be indicated if unstable, once there is no evidence of ongoing infection.

#### Implant Breakage

Breakage will necessitate removal and replacement if associated with failure of fusion or implant migration.

Other conditions that may lead to further surgery, but not necessarily explantation of the cage include:

- residual disc or recurrent herniation associated with pain
- spontaneous or traumatic bone fractures
- marked subsidence of cage

## Anterior Lumbar Interbody Fusion (ALIF) with the Asfora Bullet Cage®

### Step One: Magnetic Resonance Imaging Analysis

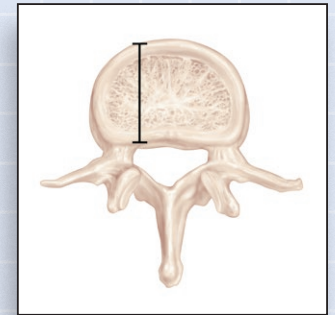
- Before scrubbing, the surgeon should check the patient's MRI films. Axial cuts should be measured for anterior-posterior diameter of the vertebrae to be fused (Fig. III-1A).
- If the diameter is greater than 35 mm, a 25 mm length cage should be used. If the diameter is smaller than 35 mm, a 21 mm cage is preferred.
- On the sagittal views, the disc space height is also measured; however, the final decision regarding diameter of the cage is made intraoperatively (Fig. III-1B).

### Step Two: Patient Positioning and Skin Marking

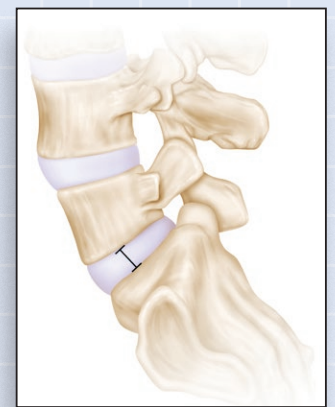- The patient should be positioned supine on the operative table.
- A pad is placed under the lumbar spine to maintain lordosis and the arms are positioned 90 degrees to the torso on boards to better facilitate radiographic imaging (Fig. III-2).
- The patient should now be prepped and draped per standard protocol.
- Intraoperative fluoroscopy in the lateral and anterior-posterior planes is positioned on both sides of the patient, to be used following exposure of the spine by the General Surgeon or Vascular Surgeon.

### Step Three: Exposure of the Spine

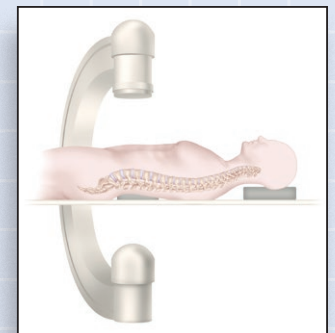
- This is carried out by the General Surgeon or Vascular Surgeon per their standard protocol.
- A midline or low transverse incision, or paramedian incision, is typically the incision of choice which will be utilized by the opening surgeon, and a retroperitoneal plane is developed for adequate exposure of the spine. The left psoas, great vessels, left ureter, and left sympathetic trunk are identified and protected from injury. Electrocautery of any kind must be used very sparingly, if at all in the tissues around and between the great vessels and the anterior surface of the spine in order to minimize risk of injury to the autonomic nerve plexus. This plexus is thought to be involved with the known complication of retrograde ejaculation.
- Normally the exposure will reveal the L5-S1 disc level to be below the bifurcation of the great vessels, while the L4-5 level and above levels, require that the left iliac vein/vena cava be mobilized to the right lateral margin of the spine (Fig. III-3). The middle sacral vessels, segmental vessels, above the disc to be fused, and the ascending lumbar vein, may need to be identified, ligated and sectioned to provide adequate exposure without excessive traction on the great vessels.
- Once the spine has been adequately exposed the spine specialist takes over, assisted by the opening surgeon, until the cage(s) is inserted.



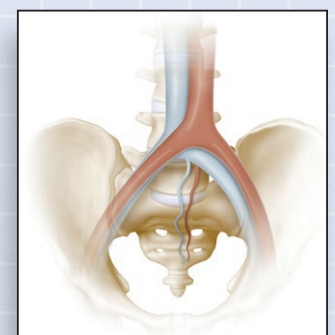
(Fig. III-1A)



(Fig. III-1B)



(Fig. III-2)



(Fig. III-3)

## Section III

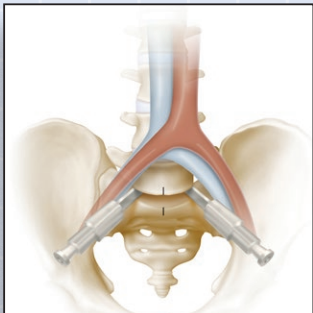
### Anterior Lumbar Interbody Fusion (ALIF) with the Asfora Bullet Cage®

#### Step Four: Decompression and Approach

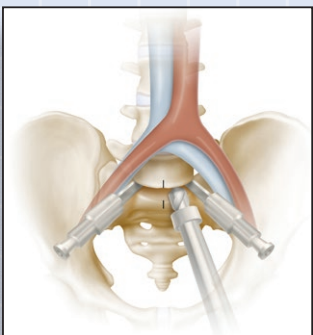
- Normally, a limited decompression is performed with the ALIF as the dural sac and exiting roots are not visualized. Removal of the disc may provide the desired decompression of the dural sac.

#### Step Five: Preparation of the Disc Space and Cage Insertion

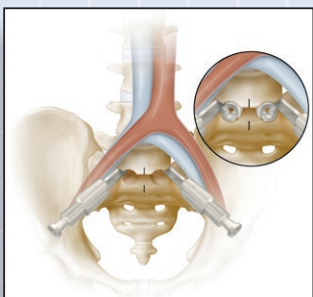
- Following complete exposure of the anterior aspect of the spine, a pin or needle is inserted approximately in the midline. An anterior-posterior radiograph is taken to verify the location of the midline. Identification and radiographic identification of the landmark is critical to ensure accurate bilateral implant placement.
- The annulus fibrosus is incised and the disc is removed in the usual manner. Two disc space distractors of the same size are selected and then inserted off the midline on both sides. These distractors not only distract the disc space, but protect the surrounding vessels (Fig. III-5A).
- If desired, the disc space may be drilled on each side of the midline or the cage may be implanted without any additional drilling if the fusion surface has been well prepared with curettes and reamers. Utilization of the drill stoppers is prudent in order to have consistent depth and avoid neural injury (Fig. III-5B). Fluoroscopy is utilized to monitor position of the drill.
- Two parallel cages are usually implanted on each side of the midline, or a single, midline cage may suffice. It is critical to observe the angle of the distractors when drilling or reaming of the disc space, in order to avoid damage to the vertebral bodies and facilitate cage insertion. Fluoroscopy also assists in the proper assessment of direction and depth of the cage (Fig. III-5C).
- Bone may be harvested from the anterior iliac crest to fill the cage(s). Alternatively, allograft bone or bone growth stimulator such as bone morphogenetic protein (BMP) may be used to fill the cage.
- The cage should be at least 4 mm larger than the distractors used to obtain adequate purchase. The large, sharp, self-tapping, angled-back threads of the ABC will penetrate the cortical surface of the vertebral bodies for a secure fit, preventing expulsion and eventual promotion of fusion.
- The threaded cage caps are then applied to close the cages.



(Fig. III-5A)



(Fig. III-5B)



(Fig. III-5C)

#### Step Six: Wound Closure

- Once the cage(s) is inserted and secure, the opening surgeon then closes the laparotomy as per standard protocol.

## Section III

### Anterior Lumbar Interbody Fusion (ALIF) with the Asfora Bullet Cage®

#### Postoperative Care

On the day following surgery, ambulate the patient with a Warm’N’Form lumbar brace. The brace should be worn for a minimum of six weeks. The patient may be ready for discharge one to three days following surgery. Schedule follow-up visits as per standard Follow-up protocol.

#### Revision, Removal or Replacement

Circumstances can develop post-implant that may require revision of the implant site or surrounding area, removal or replacement of the implanted device. The most frequent reason(s) for further surgery post-implant are discussed below.

#### Failure of Fusion (non-union)

The diagnosis of non-union should only be entertained two years following implant of the ABC. Symptomatic patients should undergo x-rays in flexion and extension, and a CT scan of the LS spine. The diagnosis of pseudoarthrosis is confirmed if motion is present at the implanted level, usually accompanied by radiolucent shades around the cage and failure of new bone formation. Further surgical intervention in these cases is usually indicated. Surgical options include the use of supplemental fixation such as the use of pedicle screws and posterior lateral fusion.

#### Implant Migration or Misplacement

In this instance, no action is needed unless the cage compresses neural or vascular elements or is significantly (>25%) out of the disc space. If the cage protrudes beyond 25%, cage removal and replacement is employed, and again the exposure is carried out by the General or Vascular Surgeon. The extruded cage is removed and replaced by a larger cage. In some instances of late cage migration, the General Surgeon may elect not to surgically intervene in view of scar formation where there may be increased risk of bowel, ureter, neural or vascular injury, and therefore further stabilization of the spine would be done through a posterior approach.

#### Infection

If there is clinical and radiological evidence of disc space infection, the cage should be removed and not replaced (see Fusion Failure above). Natural fusion may occur over time without any instrumentation. Re-fusion of the involved vertebral level may be indicated if unstable, once there is no evidence of ongoing infection.

#### Implant Breakage

Breakage will necessitate removal and replacement if associated with failure of fusion or implant migration.

Other conditions that may lead to further surgery, but not necessarily explantation of the cage include:

- residual disc or recurrent herniation associated with pain
- spontaneous or traumatic bone fractures
- marked subsidence of cage



**MEDICAL  
DESIGNS** LLC.

*Surgical Instruments Designed by Medical Professionals*

6709 South Minnesota Avenue, Suite 204, Sioux Falls, SD 57108

Phone: (888) 276-7271 Fax: (605) 335-3734

[www.medicaldesignsllc.com](http://www.medicaldesignsllc.com)